

# Autopsy findings in cases of fatal COVID-19 vaccine-induced myocarditis

Nicolas Hulscher<sup>1\*</sup> , Roger Hodkinson<sup>2</sup>, William Makis<sup>2,3</sup> and Peter A. McCullough<sup>2,4,5</sup> 

<sup>1</sup>University of Michigan School of Public Health, Ann Arbor, MI, USA; <sup>2</sup>The Wellness Company, Boca Raton, FL, USA; <sup>3</sup>Cross Cancer Institute, Alberta Health Services, Edmonton, Canada; <sup>4</sup>Truth for Health Foundation, Tucson, AZ, USA; and <sup>5</sup>McCullough Foundation, Dallas, TX, USA

## Abstract

COVID-19 vaccines have been linked to myocarditis, which, in some circumstances, can be fatal. This systematic review aims to investigate potential causal links between COVID-19 vaccines and death from myocarditis using post-mortem analysis. We performed a systematic review of all published autopsy reports involving COVID-19 vaccination-induced myocarditis through 3 July 2023. All autopsy studies that include COVID-19 vaccine-induced myocarditis as a possible cause of death were included. Causality in each case was assessed by three independent physicians with cardiac pathology experience and expertise. We initially identified 1691 studies and, after screening for our inclusion criteria, included 14 papers that contained 28 autopsy cases. The cardiovascular system was the only organ system affected in 26 cases. In two cases, myocarditis was characterized as a consequence from multisystem inflammatory syndrome. The mean age of death was 44.4 years old. The mean and median number of days from last COVID-19 vaccination until death were 6.2 and 3 days, respectively. We established that all 28 deaths were most likely causally linked to COVID-19 vaccination by independent review of the clinical information presented in each paper. The temporal relationship, internal and external consistency seen among cases in this review with known COVID-19 vaccine-induced myocarditis, its pathobiological mechanisms, and related excess death, complemented with autopsy confirmation, independent adjudication, and application of the Bradford Hill criteria to the overall epidemiology of vaccine myocarditis, suggests that there is a high likelihood of a causal link between COVID-19 vaccines and death from myocarditis.

**Keywords** Myocarditis; Sudden death; Autopsy; COVID-19; COVID-19 vaccines; mRNA; SARS-CoV-2 vaccination

Received: 9 November 2023; Accepted: 28 December 2023

\*Correspondence to: Nicolas Hulscher, University of Michigan School of Public Health, Ann Arbor, MI, USA. Email: nichulscher@gmail.com  
A previous iteration of this manuscript was posted on the [Preprints.org](https://preprints.org) preprint server on 18 July 2023.

## Introduction

As of 6 July 2023, SARS-CoV-2 has infected ~767 726 861 individuals around the world, causing 6 948 764 deaths.<sup>1</sup> The US government, in reaction to the pandemic, implemented the Operation Warp Speed (OWS) initiative. This resulted in the development and administration of the first doses of COVID-19 vaccine in <11 months after the identification of the SARS-CoV-2 genetic sequence.<sup>2</sup> This marked the most rapid development of a vaccine in history; however, there was insufficient time and investigation to adequately establish cardiovascular safety.<sup>2</sup> At the time of writing, ~70% of the world population have been vaccinated with at least one dose of a COVID-19 vaccine.<sup>1</sup>

The predominant COVID-19 vaccine platforms include messenger RNA (mRNA) (Pfizer—BioNTech—BNT162b2 and

Moderna—mRNA-1273), viral vector (AstraZeneca—ChAdOx1 nCoV-19, Johnson & Johnson—Ad26.COV2.S, and Sputnik V), and protein subunit (Novavax—NVX-CoV2373 and Zifivax—ZF2001).<sup>3</sup> mRNA and viral vector vaccines involve the bodily synthesis of the SARS-CoV-2 Spike protein as the foundation of the immune response, while protein subunit vaccines utilize injection of exogenous Spike protein, bypassing the need for genetic mechanisms.<sup>3</sup> Regardless of the vaccine platform used, circulating SARS-CoV-2 Spike protein is the likely detrimental agent through which COVID-19 vaccines cause biological harm.<sup>4–13</sup> Spike protein can initiate the breakdown and internalization of angiotensin-converting enzyme 2 (ACE2) receptors, which may disrupt the renin-angiotensin system (RAS) and lead to increased inflammation, vasoconstriction, and thrombosis.<sup>4</sup> Further, Spike protein can stimulate platelets and inflict damage to the endothelium,

which can lead to arterial and venous thrombosis.<sup>5</sup> Immune cells that have absorbed the lipid nanoparticles (LNPs) subsequently reintroduce them into the bloodstream with a higher number of exosomes carrying microRNAs and Spike protein, possibly resulting in drastic inflammation.<sup>5</sup> Long-term immune surveillance may be compromised by mRNA COVID-19 vaccines due to IRF7, IRF9, p53, and BRCA suppression.<sup>5,6</sup> There is a high probability of a causal link between COVID-19 mRNA vaccination and myocarditis, neurodegenerative disease, immune thrombocytopenia, Bell's palsy, liver disease, impaired adaptive immunity, impeded DNA damage response, and tumourigenesis.<sup>5</sup> Moreover, a recent study found that repeated COVID-19 vaccination with mRNA-based vaccines leads to the production of abnormally high concentrations of immunoglobulin G4 (IgG4) antibodies.<sup>7</sup> These antibodies can fail to neutralize Spike protein, which has been shown to circulate for at least 28 days, cause immune suppression, and promote the development of autoimmune diseases including myocarditis.<sup>7–13</sup>

In June 2021, the US Food and Drug Administration (FDA) and Centers for Disease Control and Prevention (CDC) issued a joint warning on myocarditis occurring after mRNA COVID-19 vaccination.<sup>14</sup> A PubMed search performed at the time of writing for 'myocarditis' and 'COVID-19 vaccination' yielded 994 results, indicating extensive interest in COVID-19 vaccine-induced myocarditis among researchers. Rose and McCullough found that the peak age was 18–24 years and 90% of cases were men.<sup>15</sup> Myocarditis development most commonly occurred after the second dose; however, additional cases occurred after the third dose, adding to the cumulative risk for individuals continuing with every 6 month injection schedules.<sup>15</sup> Avolio *et al.* demonstrated the cardiac pericyte as one of the several cell lines that take up mRNA, produce Spike protein, and express it on the cell surface inciting autoimmune attack.<sup>13</sup> Yonker *et al.* found that children hospitalized with myocarditis had presence of free Spike protein not neutralized by antibodies while those who were asymptomatic had appropriate neutralization of Spike protein by anti-Spike antibodies.<sup>11</sup> A biodistribution study has shown that LNPs can travel to the heart as well as other vital organs.<sup>16</sup> Baumeier *et al.* found that among 15 young individuals suffering from myocarditis who underwent cardiac biopsy, the myocardium stained for SARS-CoV-2 Spike protein and not nucleocapsid, effectively ruling out infection and leaving vaccination as the only possible source of Spike protein.<sup>17</sup> Furthermore, they found a range of pathologies from inflammatory cardiomyopathy to active myocarditis and severe giant cell myocarditis.<sup>17</sup> Detection of Spike protein and CD4<sup>+</sup> T-cell-dominated inflammation within cardiac tissue suggested vaccine-triggered autoimmune processes.<sup>17</sup> Two prospective cohort studies, by Mansanguan *et al.*<sup>18</sup> and Buerger *et al.*,<sup>19</sup> suggested that the incidence of myocarditis or troponin elevation from COVID-19 vaccine dose numbers 2 and 3 could be as high

as 2.3% and 2.8%, respectively. Because of the frequent occurrence of this problem in cardiovascular practice, the United Kingdom<sup>20</sup> and Australia<sup>21</sup> have issued clinical practice guidelines on the diagnosis and management of COVID-19 vaccine-induced myocarditis.

Up to 16 June 2023, the Vaccine Adverse Event Reporting System (VAERS) included 1 569 668 adverse event reports associated with COVID-19 vaccines, including 35 487 deaths, 27 229 myocarditis and pericarditis, and 20 184 heart attack reports.<sup>22</sup> Before the COVID-19 pandemic, Meissner reported that 86% of VAERS entries were completed by medical personnel or vaccine manufacturers and only 14% were made by the patient or their family.<sup>23</sup> Thus, VAERS has demonstrated a very strong crude signal for myocarditis as an accepted complication of COVID-19 vaccination; however, additional information can be gleaned from autopsy in cases of death that are suspected to be caused by COVID-19 immunization. In fact, Walach *et al.* stated that all deaths after COVID-19 vaccination should be investigated with an autopsy to better our understanding of the vaccines deleterious mechanisms on the human body.<sup>24</sup> Autopsies represent one of the most powerful diagnostic methods in medicine, ascertaining causes of death and elucidating the pathophysiological mechanisms of disease.<sup>25</sup> COVID-19 vaccines exhibit multiple mechanisms of injury to the cardiovascular system and are associated with a considerable number of adverse event reports, thus representing an exposure that may be causally linked to death in some myocarditis cases. This systematic review aims to investigate potential causal links between COVID-19 vaccines and death from myocarditis using post-mortem analysis.

## Methods

### Data sources and search strategy

We conducted a systematic review of all published autopsy reports involving COVID-19 vaccination-induced myocarditis through 3 July 2023. We searched PubMed and ScienceDirect using all possible combinations of the following keywords: 'COVID-19 Vaccine', 'SARS-CoV-2 Vaccine', or 'COVID Vaccination', and 'Post-mortem', 'Autopsy', or 'myocarditis'. No language restrictions were applied to the search. All included studies were examined for pertinent literature contained in their references.

### Eligibility criteria and selection process

The following inclusion criteria were used: all autopsy studies (original articles, case reports, and case series in any language) that include COVID-19 vaccine-induced myocarditis as a possible cause of death. Exclusion criteria included

articles with no reported vaccination status, articles with no autopsy results, papers without any myocarditis cases, animal studies, review articles, systematic reviews, and meta-analyses. Two authors (NH and PAM) independently reviewed the entirety of the studies retrieved to determine their eligibility for inclusion and removed any ineligible or duplicate studies. In cases where there were disagreements about including an article, the two authors engaged in a discussion until a consensus was achieved.

## Data extraction and analysis

Two authors (NH and PAM) independently extracted all individual case data (age, sex, vaccine type, dose number, period from last vaccine administration to death, and post-mortem findings) from the included studies into Microsoft Excel. If the data extracted from the included studies were not identical between the two authors, discussion and re-extraction of the data were employed until a consensus was reached. Descriptive statistics were calculated using all available data. In the calculation of mean age, estimated age values were excluded. Causality in each case was assessed in accordance with independent review by three qualified physicians with experience and expertise in cardiac pathology (PAM, RH, and WM). A quorum of two out of three was required to establish a highly probable causal link to COVID-19 vaccination. If this consensus was not reached, no causal link to vaccination could be made. The adjudicators used all available evidence (demographic information, clinical vignette, vaccination information, and post-mortem findings) and assessed any temporal relationships, the strength of evidence and their consistency with well-described COVID-19 vaccine-induced myocarditis characteristics and mechanisms, and possible alternate causes of death to evaluate causal links.

## Results

The database search yielded 1691 studies that may have met our inclusion criterion. After removing 1212 duplicate papers and screening 479 unique studies, only 12 met our inclusion criterion. A detailed screening of references found eight additional papers, with two of them fulfilling our inclusion criterion. Overall, we included 14 studies that contain 28 autopsy cases of COVID-19 vaccinees diagnosed with myocarditis (Figure 1).

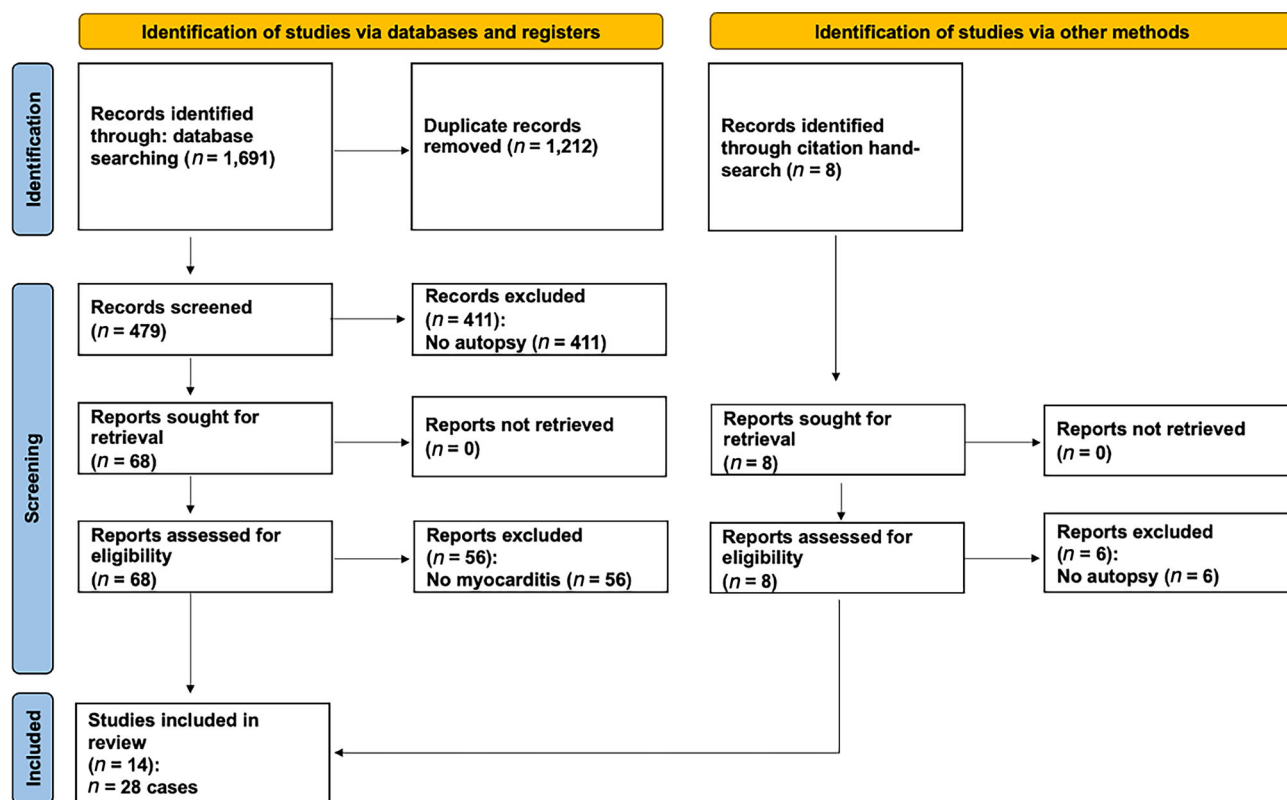
The included 14 reports<sup>26–39</sup> are summarized in Table 1. Of the 28 autopsy cases, 9 (32.1%) were female. The mean age of death was 44.4 years old. Eighteen cases (64%) received Pfizer–BioNTech vaccines, nine cases (32%) received Moderna vaccines, and one case received a Zifivax vaccine. The cardiovascular system was the only organ system af-

fected in 26 cases. In two cases, myocarditis was seen as a consequence from multisystem inflammatory syndrome (MIS) (Figure 2). The number of days from vaccination to death was 6.2 (mean) and 3 (median). Most (75%) of the deaths occurred within a week from last vaccination (Figure 3).

All 28 cases (100%) were found to have a high likelihood of being causally linked to COVID-19 vaccination in accordance with independent adjudication. Most cases had symptoms consistent with myocarditis prior to death (chest pain and effort intolerance), and in the case of Choi *et al.*, a 22-year-old Korean man died in the hospital after 7 h of intensive attempts at supportive care.<sup>33</sup> The autopsy showed intense inflammation and destruction of cardiac tissue including the conduction system. Other cases had no reported symptoms before death. Gill *et al.* reported two boys, age 16 and 17, who died a few days after mRNA injection while asleep at home.<sup>31</sup> The case reported by Takahashi *et al.* demonstrated that the proximal cause of death was an aortic dissection with coincident epicardial myocarditis, both of which were determined related to vaccination.<sup>28</sup> Suzuki *et al.* reported a series of 54 cases of which 3 are included in our analysis based on the findings of suspected concurrent myocarditis in cases with or without coincident coronary artery disease and ischaemic cardiomyopathy.<sup>30</sup> Autopsies revealed patchy inflammation suggesting that sudden arrhythmic death could have occurred due to a re-entrant ventricular arrhythmia culminating in sudden cardiac death. The authors in these cases concluded that the cause of death was COVID-19 vaccine-induced myocarditis.

## Discussion

We established that all 28 deaths were most likely causally linked to COVID-19 vaccination by independent review of the clinical information presented in each paper. Our data are consistent with the overall epidemiological literature [PubMed search for (COVID-19 vaccination) \* (myocarditis) = 994 papers] concerning COVID-19 vaccine-induced myocarditis where the Bradford Hill criteria<sup>40</sup> support causality from an epidemiological perspective. This includes biological plausibility, temporal association, internal and external validity, coherence, analogy, and reproducibility with each successive report of myocarditis-related death after COVID-19 vaccination. Baumeier *et al.*'s findings that the myocardium stained for SARS-CoV-2 Spike protein and not nucleocapsid among 15 young individuals suffering from myocarditis indicated that the sole cause of cardiac injury in post-vaccine myocarditis is highly likely to be COVID-19 vaccination, confirming our results (Figure 4).<sup>17</sup> In addition, Baumeier *et al.* found Spike protein and CD4<sup>+</sup> T-cell-dominated inflammation, suggesting the COVID-19 vaccine as the single cause of autoimmune

**Figure 1** Preferred Reporting Items for Systematic Reviews and Meta-Analyses (PRISMA) flow diagram detailing the study selection process.

reaction processes seen in myocardial histology (Figure 5).<sup>17</sup> COVID-19 vaccination and SARS-CoV-2 infection before or after one or more vaccine administrations may have contributed to cardiac Spike protein injury and inflammation in cases where infection was not ruled out. The predominant mechanism of death is most likely a sudden arrhythmia such as ventricular tachycardia or ventricular fibrillation. Relatively few cases had antecedent fulminant pump failure. These data are concerning when considered in light of young individuals, particularly male athletes who have had sudden death after vaccination without an autopsy. Polykretis and McCullough have reported that, among professional and semi-professional European athletes <35 years old, compared with a stable period before the pandemic, the annualized rate of sudden death since the rollout of COVID-19 vaccines has increased 10-fold.<sup>41</sup> Cadejani has postulated that a surge of catecholamines can be the trigger for COVID-19 vaccine-induced sudden death,<sup>42</sup> which could explain the occurrence during exercise and sports as well as during the early morning waking hours from sleep where there is a surge of epinephrine and norepinephrine.<sup>43</sup>

Our findings escalate concerns regarding COVID-19 vaccine-induced myocarditis and its mechanisms, particularly in cases of sudden unexpected death in younger individuals

where there is no other explanation. COVID-19 vaccine Spike protein is produced in the body for an uncontrolled duration and in unknown quantity resulting in deleterious effects,<sup>4–13</sup> especially on the heart,<sup>10,11,13–21</sup> explaining the cardiovascular deaths seen in our study without evidence of other organ system involvement. MIS has been identified following COVID-19 vaccination in both children<sup>44</sup> and adults<sup>45</sup>; however, we found only two autopsy cases with this diagnosis. MIS may be caused by the systemic distribution of the LNPs containing mRNA after vaccine administration<sup>16</sup> and consequent systemic Spike protein expression on cell surfaces that results in extensive inflammation. Considering the average time of 6.2 days between vaccination and death, a temporal link between COVID-19 vaccination and death is corroborated by the observation that SARS-CoV-2 mRNA Spike vaccine sequences can persist in the bloodstream for at least 28 days after vaccination.<sup>12</sup>

Ittiwut *et al.* have found that genetic susceptibility to sudden death may explain some of the variation.<sup>46</sup> Polymorphisms in the SCN5A channel were associated with the highest rates of sudden death in their study.<sup>46</sup> The overwhelming predominance of men among COVID-19 vaccine-induced myocarditis cases<sup>15</sup> and with other vaccines including smallpox and influenza<sup>47</sup> suggests that androgen

**Table 1** Case information from all included studies of autopsy-confirmed COVID-19 vaccine-induced myocarditis

Author	Case	Age	Sex	Vaccine	Dose <sup>a</sup>	Disease	Period <sup>b</sup>	Post-mortem findings
Nushida, 2023 (Japan) <sup>26</sup>	1	14	F	Pfizer	3	MIS, myopericarditis	2 days	Congestive oedema of the lungs, T-cell lymphocytic and macrophage infiltration in the lungs, pericardium, and myocardium of the left atria and left ventricle, liver, kidneys, stomach, duodenum, bladder, and diaphragm. The presence of foci centred on the atria and breathlessness are the findings that led to the diagnosis that the cause of death was vaccine-related myopericarditis, which led to severe arrhythmias and progressive heart failure.
Mörz, 2022 (Germany) <sup>27</sup>	1	76	M	Pfizer	2	Encephalitis, myocarditis	21 days	Signs of aspiration pneumonia and systemic arteriosclerosis were evident. Brain examination uncovered acute vasculitis (predominantly lymphocytic) as well as multifocal necrotizing encephalitis of unknown aetiology with pronounced inflammation including glial and lymphocytic reaction. In the heart, signs of chronic cardiomyopathy as well as mild acute lympho-histiocytic myocarditis and vasculitis were present. Only Spike protein but no nucleocapsid protein could be detected within the foci of inflammation in both the brain and the heart. Also, mild acute splenitis, gastric mucosal bleeding, liver lipofuscinosis, and mild active nephritis were found.
Takahashi, 2022 (Japan) <sup>28</sup>	1	'90s'	M	Pfizer	3	Pericarditis	14 days	Dissection of the ascending aorta and pericardial hemotamponade. The heart showed a white villous surface, and the pericardium was fibrously thick. Microscopic examination revealed pericarditis with predominantly macrophage and lymphocyte infiltration. The heart showed moderate dilatation of both ventricles, and the myocardium showed an uneven colour change and decreased elasticity. Histologically, severe myocarditis with extensive myocytolysis was observed. The myocarditis showed severe inflammatory cell infiltration with T-lymphocyte and macrophage predominance, and vast nuclear dust accompanying neutrophilic infiltration was observed. In the bone marrow and lymph nodes, hemophagocytosis was observed. SARS-CoV-2 nucleic acids were not detected using multiviral real-time PCR system.
Satomi, 2022 (Japan) <sup>29</sup>	1	61	F	Pfizer	1	Myocarditis	10 days	Old myocardial infarction in the post-lateral wall, severe coronary artery sclerosis, leucocyte and lymphocyte infiltration in the left anterior wall, diabetic nephropathy, and aortic sclerosis.
Suzuki, 2021 (Japan) <sup>30</sup>	1	91	M	Moderna	1	Ischaemic heart disease, myocarditis	6 days	Scattered necrosis and fibrosis of cardiomyocytes with a perivascular pattern of inflammatory cell infiltration (consisting of predominantly lymphocytes).
	2	24	M	Moderna	2	Myocarditis	3 days	Scattered inflammatory cell infiltration (consisting of predominantly monocytes) in the interstitial space of cardiomyocytes/around the coronary arteries, interstitial
	3	39	M	Moderna	2	Myocarditis	3 days	

(Continues)



Table 1 (continued)

Author	Case	Age	Sex	Vaccine	Dose <sup>a</sup>	Disease	Period <sup>b</sup>	Post-mortem findings
Gill, 2022 (USA) <sup>31</sup>	1	'Teenage'	M	Pfizer	2	Myocarditis	3 days	oedema, eosinophilic and wavy change of cardiomyocytes, lung oedema, and coronary sclerosis. No molecular evidence of SARS-CoV-2 infection. Global myocardial injury with areas of coagulative myocytolysis and contraction bands, with a perivascular pattern of inflammation consisting of mainly neutrophils and histiocytes, scant lymphocytes, and occasional eosinophils. No acute or organizing thrombi were detected. Pattern of injury is consistent with stress cardiomyopathy.
	2	'Teenage'	M	Pfizer	2	Myocarditis	4 days	No molecular evidence of SARS-CoV-2 infection. As with the previous case, global myocardial injury was found but with more widespread transmural ischaemic changes and more interstitial inflammation. Subepicardial distribution of injury was not seen. No acute or organizing thrombi were detected.
Ameratunga, 2022 (New Zealand) <sup>32</sup>	1	57	F	Pfizer	1	Myocarditis	3 days	Left pleural mass originating from the mediastinum was found. Multifocal inflammatory cell infiltration in the myocardium and areas of eosinophil-rich inflammatory aggregates with myocyte necrosis were found. An abundant eosinophilic infiltrate with myocyte necrosis was observed. Antibodies to SARS-CoV-2 were not detected.
Choi, 2021 (Korea) <sup>33</sup>	1	22	M	Pfizer	1	Myocarditis	5 days	Histological examination of the heart showed isolated atrial myocarditis, with neutrophil and histiocyte predominance. Immunohistochemical C4d staining showed scattered single-cell necrosis of myocytes, which was not accompanied by inflammatory infiltrates. Extensive contraction band necrosis was seen in the atria and ventricles. There was no evidence of microthrombosis or infection in the heart and other organs.
Schneider, 2021 (Germany) <sup>34</sup>	1	65	M	Pfizer	1	Myocarditis	1 day	Severe coronary sclerosis, massive cardiac hypertrophy, myocardial infarction scars, myocarditis, and anaphylaxis diagnostics negative.
Verma, 2021 (USA) <sup>35</sup>	1	42	M	Moderna	2	Myocarditis	~14 days	Autopsy revealed biventricular myocarditis. An inflammatory infiltrate admixed with macrophages, T cells, eosinophils, and B cells was also observed.
Schwab, 2023 (Germany) <sup>36</sup>	1	46	M	Pfizer	1	Myocarditis	0 days	Histological examination showed inflammatory infiltration of the myocardium. The infiltrate was focal and interstitial. It was predominantly detected in sections taken from the RV wall and interventricular septum. The histological and immunohistochemical characterization revealed that the inflammatory infiltrate was predominantly composed of lymphocytes. Microfocal myocyte injury was demonstrable. Lacked pre-existing, clinically relevant heart disease.

(Continues)

Table 1 (continued)

Author	Case	Age	Sex	Vaccine	Dose <sup>a</sup>	Disease	Period <sup>b</sup>	Post-mortem findings
	2	50	F	Moderna	1	Myocarditis	1 day	Histological examination showed inflammatory infiltration of the myocardium. The infiltrate was focal and interstitial. It was predominantly detected in sections taken from the RV wall and interventricular septum. The histological and immunohistochemical characterization revealed that the inflammatory infiltrate was predominantly composed of lymphocytes. Microfocal myocyte injury was demonstrable. An inflammatory infiltration of the epicardium and the subepicardial fat tissue was concomitantly found. Lacked pre-existing, clinically relevant heart disease.
	3	62	F	Pfizer	1	Myocarditis	7 days	Histological examination showed inflammatory infiltration of the myocardium. The infiltrate was focal and interstitial. It was predominantly detected in sections taken from the RV wall and interventricular septum. The histological and immunohistochemical characterization revealed that the inflammatory infiltrate was predominantly composed of lymphocytes. Microfocal myocyte injury was demonstrable. An inflammatory infiltration of the epicardium and the subepicardial fat tissue was concomitantly found. Lacked pre-existing, clinically relevant heart disease.
	4	55	M	Pfizer	2	Myocarditis	4 days	Histological examination showed inflammatory infiltration of the myocardium. The infiltrate was focal and interstitial. It was predominantly detected in sections taken from the RV wall and interventricular septum. The histological and immunohistochemical characterization revealed that the inflammatory infiltrate was predominantly composed of lymphocytes. An inflammatory infiltration of the epicardium and the subepicardial fat tissue was concomitantly found. Lacked pre-existing, clinically relevant heart disease.
	5	75	F	Pfizer	1	Myocarditis	1 day	Histological examination showed inflammatory infiltration of the myocardium. The infiltrate was focal and interstitial. It was predominantly detected in sections taken from the RV wall and interventricular septum. The histological and immunohistochemical characterization revealed that the inflammatory infiltrate was predominantly composed of lymphocytes. An inflammatory infiltration of the epicardium and the subepicardial fat tissue was concomitantly found. Lacked pre-existing, clinically relevant heart disease. Analysis for potential infectious agents causing a myocarditis revealed low viral copy numbers of human herpes virus 6.

(Continues)

Table 1 (continued)

Author	Case	Age	Sex	Vaccine	Dose <sup>a</sup>	Disease	Period <sup>b</sup>	Post-mortem findings
Hoshino, 2022 (Japan) <sup>37</sup>	1	27	M	Moderna	1	Myocarditis	36 days	An autopsy revealed asymmetric LV hypertrophy, thickening of the RV wall (550 g; LV wall, 11–16 mm; RV wall, 5–7 mm), myxomatous degeneration of the posterior leaflet of the mitral valve, and hypertrophy of the posteromedial papillary muscle. Microscopic findings revealed that cardiac myocytolysis and widespread fibrosis were observed, and significant mixed inflammatory infiltration (T cells, macrophages, and eosinophils) was observed in the LV free wall and the anterior portion of the ventricular septum.
Dong, 2022 (China) <sup>38</sup>	1	34	F	Zifivax	1	Myocarditis	12 days	Autopsy showed severe interstitial myocarditis, including multiple patchy infiltrations of lymphocytes and monocytes in the myocardium of the LV and RV walls associated with myocyte degeneration and necrosis.
Cho, 2023 (Korea) <sup>39</sup>	1	22	M	Pfizer	1	SCD from myocarditis	6 days	Diffuse inflammatory infiltration, with neutrophil and histiocyte predominance in both atria and near AV node and SA node. Free of inflammatory infiltrates in ventricular myocardium.
	2	30	F	Pfizer	1	SCD from myocarditis	3 days	Diffuse inflammatory cell infiltration, myocardial fibre disarray, interstitial fibrosis, and localized necrosis of myocyte.
	3	45	M	Pfizer	2	SCD from myocarditis	3 days	Localized infiltration of neutrophils, lymphocytes, histiocyte, and a few eosinophils was noted. A small number of cardiomyocyte necroses were also seen.
	4	25	M	Pfizer	2	SCD from myocarditis	3 days	Autopsy revealed myocarditis.
	5	45	M	Pfizer	2	SCD from myocarditis	3 days	Interstitial infiltration of various inflammatory cells including lymphocyte, neutrophil, eosinophil, and focal necrosis suggesting the diagnosis of myocarditis.
	6	36	F	Moderna	1	SCD from myocarditis	2 days	Neutrophil, eosinophil, and histiocyte infiltration in the myocardium suggesting acute myocarditis.
	7	33	M	Moderna	2	SCD from myocarditis	1 day	Multiple focal infiltrations of acute inflammatory cells and chronic inflammatory cells in the myocardium.
	8	33	M	Moderna	2	SCD from myocarditis	3 days	Various inflammatory cells such as neutrophils, eosinophils, lymphocytes, macrophages, and cardiomyocyte necrosis in the myocardial interstitium and epicardium suggested myocarditis.

AV, atrioventricular; LV, left ventricular; MIS, multisystem inflammatory syndrome; RV, right ventricular; SA, sinoatrial; SCD, sudden cardiac death.

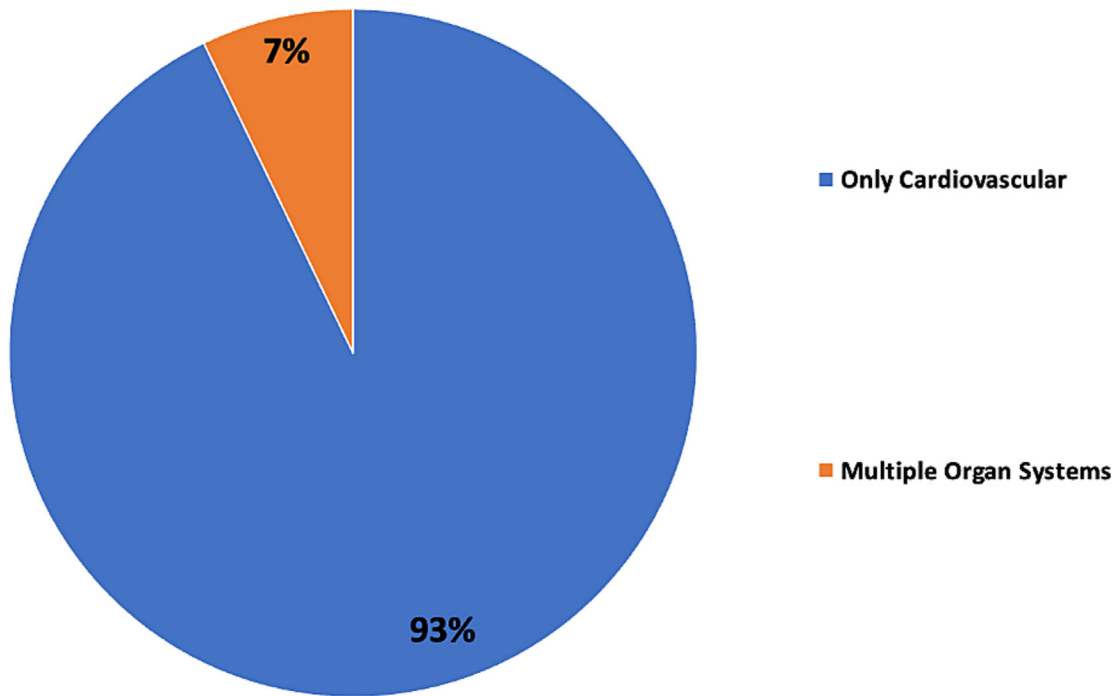
<sup>a</sup>‘~’ indicates inferred period (estimated period using all available information).

<sup>b</sup>Dose = total number of vaccine doses received.

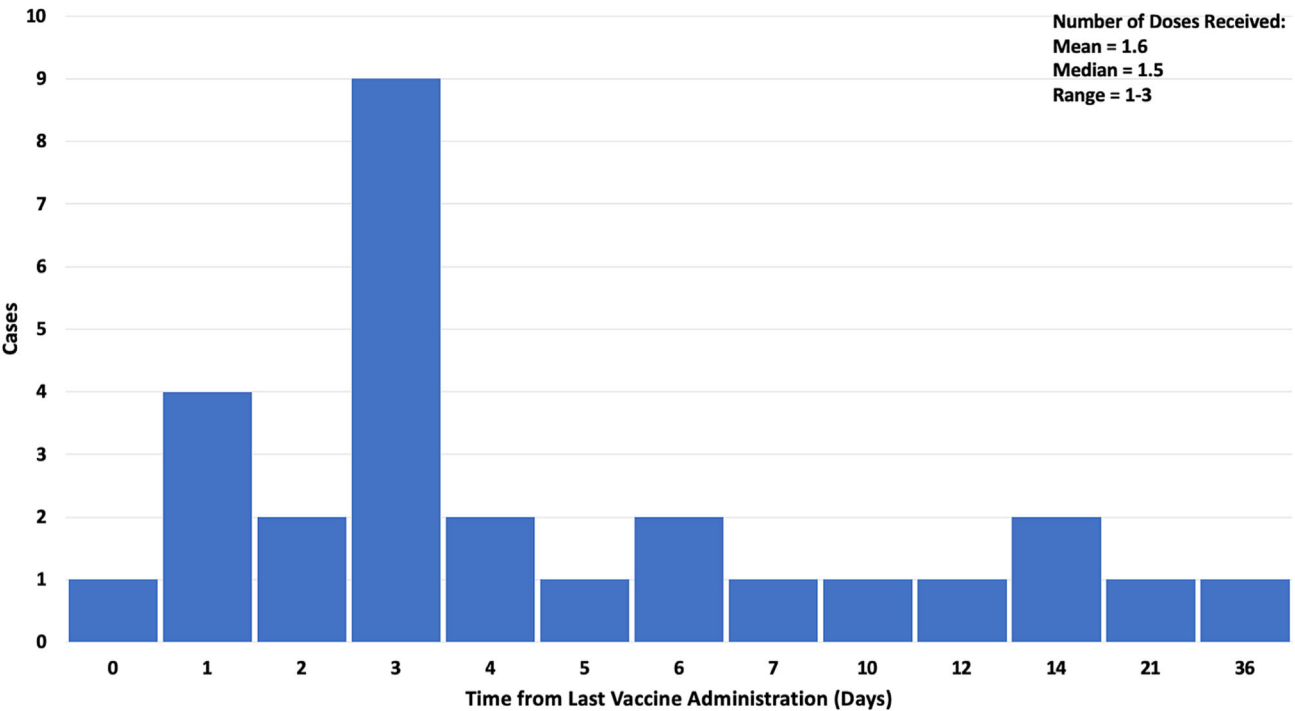
<sup>c</sup>Period = days from most recent vaccine administration to death.



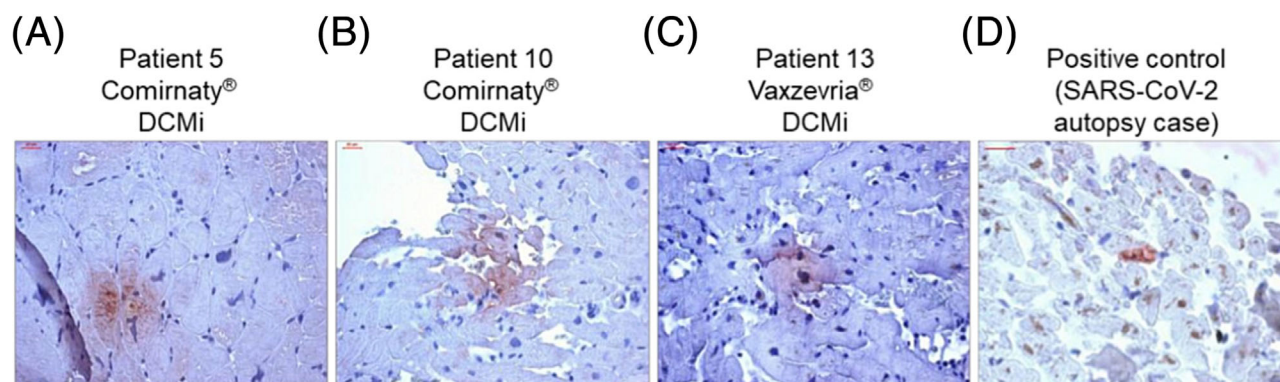
**Figure 2** Proportion of cases by affected organ system.



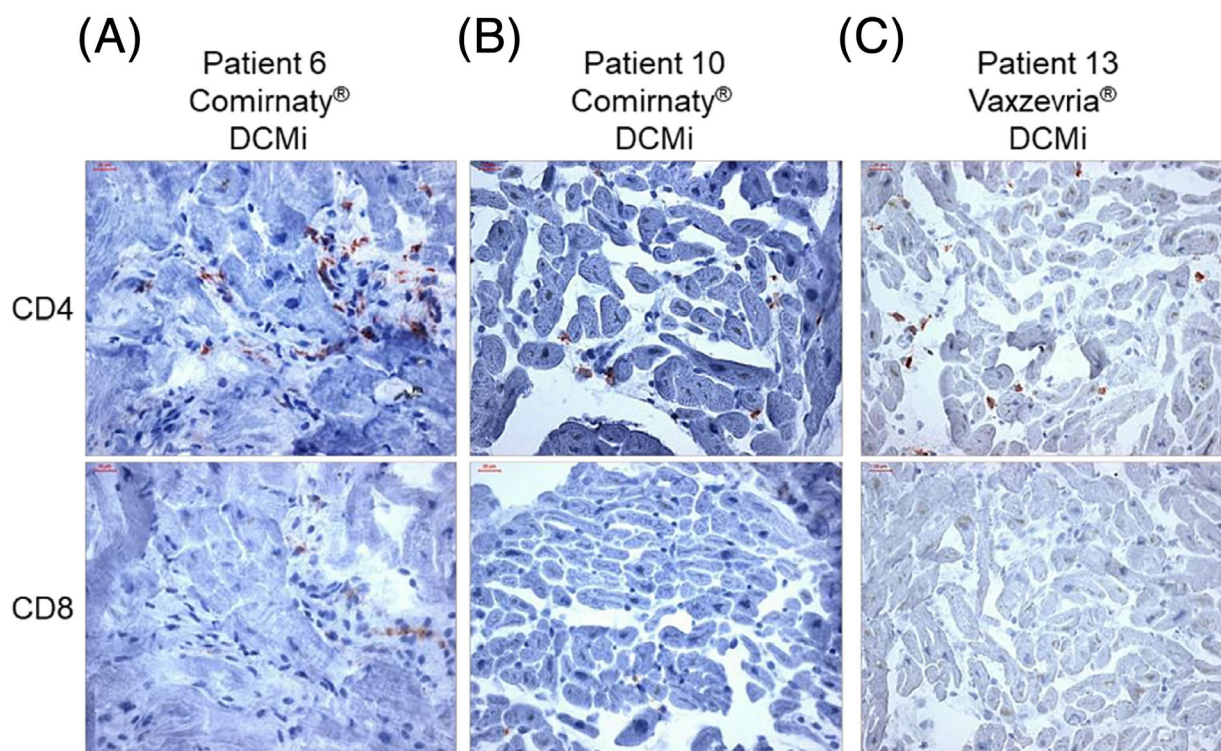
**Figure 3** Distribution of time from last vaccine administration to death.



**Figure 4** Evidence of SARS-CoV-2 Spike protein in cardiac tissue after COVID-19 vaccination. Representative immunohistochemical stainings of SARS-CoV-2 Spike protein in endomyocardial biopsies from patients diagnosed with inflammatory dilated cardiomyopathy (DCMi) after receiving Comirnaty® [(A, B) Patients 5 and 10] or Vaxzevria® [(C) Patient 13]. (D) SARS-CoV-2-positive cardiac tissue served as positive control. Magnification  $\times 400$ . Scale bars: 20  $\mu$ m. Figure and legend reprinted from Baumeier *et al.*<sup>17</sup> Permission to use this figure has been granted in accordance with the open access Creative Commons CC BY 4.0 licence.



**Figure 5** Inflammatory cardiomyopathy in response to COVID-19 vaccination is dominated by CD4<sup>+</sup> T cells. Representative immunohistochemical stainings of CD4<sup>+</sup> and CD8<sup>+</sup> T cells in endomyocardial biopsies from patients diagnosed for inflammatory dilated cardiomyopathy (DCMi) after receiving Comirnaty® [(A, B) Patients 6 and 10] or Vaxzevria® [(C) Patient 13] vaccines, respectively. Magnification  $\times 400$ . Scale bars: 20  $\mu$ m. Figure and legend reprinted from Baumeier *et al.*<sup>17</sup> Permission to use this figure has been granted in accordance with the open access Creative Commons CC BY 4.0 licence.

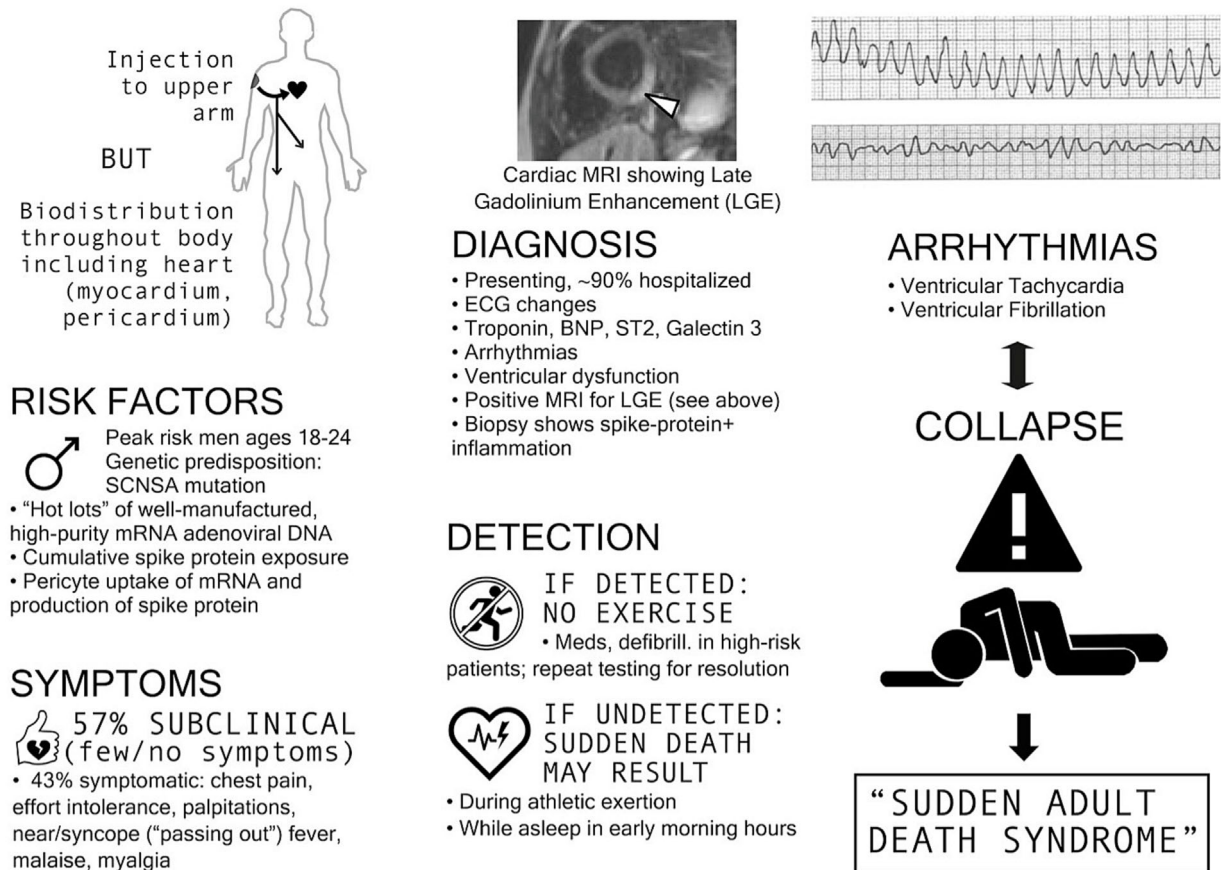


receptors or some other undiscovered interaction with male hormones may play a role in the manifestation of vaccine-induced myocarditis.

Figure 6 highlights the major steps in COVID-19 vaccine-induced myocarditis. Baseline susceptibility includes male gender, age 18–24, SCN5A polymorphisms, and athletic

**Figure 6** COVID-19 vaccine-induced myocarditis characteristics.

# mRNA “VACCINE” → MYOCARDITIS → OUTCOMES



tendency with surges of catecholamines in routine sports activities and during sleep. Some batches/vials of mRNA may have more concentrated LNP–mRNA complexes or cDNA contaminants as suggested by Schmeling *et al.*, who found that ~4.2% of vials are responsible for >70% of serious adverse events.<sup>48</sup> The LNPs loaded with mRNA are known to systemically circulate for 28 days or more; thus, there are many cycles of coronary flow and cardiac uptake of the LNP–mRNA complex.<sup>12,49</sup> These data indicate that the mRNA sequences are long-lasting and durable within pericytes, cardiomyocytes, and other cell lines, providing the genetic instructions for the continuous production of Spike protein, which is expressed on cell surfaces and in the interstitial space, which can incite a deleterious autoimmune reaction. According to Mansanguan *et al.*, 57% of myocarditis cases may be asymptomatic.<sup>18</sup> Among those with symptoms, >90% are hospitalized with clinical and diagnostic features including chest pain, heart failure, electrocardiogram (ECG) changes, positive troponin levels, and cardiac MRI imaging demonstrating patchy late gadolinium enhancement.<sup>50</sup> If unde-

tected, risks include sudden cardiac death during sports or sleep where ~65% cannot be resuscitated<sup>41</sup> and are classified as sudden adult death syndrome (SADS). In such cases, it is important to document the brand, number of doses, inoculation dates, lot numbers, and, as our data indicate, procurement of an autopsy.

Vaccines have played an important role in the advancement of immunology, leading to strategies of prevention, and lessening the burden of infectious diseases. Vaccines, while preventative, may fail as treatment to end pandemics with highly prevalent infections.<sup>51</sup> Some immunizations as we have learned, including the COVID-19 vaccine, can have significant side effects. Myocarditis may be a significant contributor to overall deaths observed after COVID-19 vaccination. The studies analysed in this review are consistent with multiple studies that show excess mortality after vaccination, which may have occurred due to myocarditis that was not detected before sudden death. Pantazatos and Seligmann reported that all-cause mortality increased in most age groups up to 5 weeks after vaccination resulting in 146 000 to



187 000 vaccine-associated deaths in the United States by August 2021.<sup>52</sup> Skidmore elucidated that 278 000 Americans may have died from the COVID-19 vaccine by December 2021.<sup>53</sup> These findings were corroborated by Aarstad and Kvitastein, who reported that, among European countries, a higher COVID-19 vaccine uptake in 2021 was associated with increased all-cause mortality in the first 9 months of 2022 after accounting for alternative explanations.<sup>54</sup> Excess deaths not caused by COVID-19 have been identified worldwide after the mass COVID-19 vaccination programmes began,<sup>55–60</sup> indicating the presence of a novel detrimental exposure among populations. Pantazatos and Seligmann extrapolated that VAERS reports are underreported by a factor of 20.<sup>52</sup> When this factor is applied to the 16 June 2023 VAERS death report count of 35 487,<sup>22</sup> the number of deaths in the United States and other countries that use VAERS becomes 709 740. Please note that this extrapolation is a general estimate and may not be accurate. Nonetheless, if the sizeable number of fatalities was to be confirmed, the COVID-19 vaccines would constitute the largest biological safety disaster in human history.

Our paper has all the limitations of small sample sizes derived from assembling case reports or series. These include selection bias of cases for autopsy, publication bias against disclosing more cases from academic medical centres and medical examiners for fear of reprisal, and unknown confounders such as undetected cardiotropic pathogens, alcohol abuse, and drug abuse, which are all threats to validity.

In summary, we identified a series of myocarditis-related deaths following COVID-19 vaccination, confirmed with au-

topsies, to provide the medical community with a more comprehensive understanding of fatal COVID-19 vaccine-induced myocarditis. The temporal relationship, internal and external consistency seen among cases in this review with known COVID-19 vaccine-induced myocarditis, its pathobiological mechanisms, and related excess death, complemented with autopsy confirmation, independent adjudication, and application of the Bradford Hill criteria to the overall epidemiology of vaccine myocarditis, suggests that there is a high likelihood of a causal link between COVID-19 vaccines and death from myocarditis. This may also apply to some cases where sudden, unexpected death has occurred in a vaccinated person. If the COVID-19 vaccines remain on the market for public use, urgent investigation is required for the purpose of risk stratification and mitigation in order to reduce the population occurrence of fatal COVID-19 vaccine-induced myocarditis.

## Conflict of interest

R.H., W.M., and P.A.M. are either affiliated with or receive salary support (modest) or equity (modest) in The Wellness Company, which had no role in the study.

## Funding

No funding was received for conducting this study.

## References

1. WHO COVID-19 dashboard [Internet]. World Health Organization; [cited 2023 May 17]. Available from: <https://covid19.who.int/>. Accessed 17 May 2023
2. Kuter BJ, Offit PA, Poland GA. The development of COVID-19 vaccines in the United States: Why and how so fast? *Vaccine* 2021;**39**:2491–2495. doi:10.1016/j.vaccine.2021.03.077
3. Graña C, Ghosn L, Evrenoglou T, Jarde A, Minozzi S, Bergman H, *et al.* Efficacy and safety of COVID-19 vaccines. *Cochrane Database Syst Rev* 2022;**7**: CD015477. doi:10.1002/14651858.CD015477
4. Trougakos IP, Terpos E, Alexopoulos H, Politou M, Paraskevis D, Scorilas A, *et al.* Adverse effects of COVID-19 mRNA vaccines: The spike hypothesis. *Trends Mol Med* 2022;**28**:542–554. doi:10.1016/j.molmed.2022.04.007
5. Seneff S, Nigh G, Kyriakopoulos AM, McCullough PA. Innate immune suppression by SARS-CoV-2 mRNA vaccinations: The role of G-quadruplexes, exosomes, and microRNAs. *Food Chem Toxicol* 2022;**164**:113008. doi:10.1016/j.fct.2022.113008
6. Singh N, Bharara SA. S2 subunit of SARS-nCoV-2 interacts with tumor suppressor protein p53 and BRCA: An in silico study. *Transl Oncol* 2020;**13**:100814. doi:10.1016/j.tranon.2020.100814
7. Uversky VN, Redwan EM, Makis W, Rubio-Casillas A. IgG4 antibodies induced by repeated vaccination may generate immune tolerance to the SARS-CoV-2 spike protein. *Vaccines (Basel)* 2023;**11**:991. doi:10.3390/vaccines11050991
8. Theoharides TC. Could SARS-CoV-2 spike protein be responsible for long-COVID syndrome? *Mol Neurobiol* 2022;**59**:1850–1861. doi:10.1007/s12035-021-02696-0
9. Theoharides TC, Conti P. Be aware of SARS-CoV-2 spike protein: There is more than meets the eye. *J Biol Regul Homeost Agents* 2021;**35**:833–838. doi:10.23812/THEO\_EDIT\_3\_21
10. Bozkurt B, Kamat I, Hotez PJ. Myocarditis with COVID-19 mRNA vaccines. *Circulation* 2021;**144**:471–484. doi:10.1161/CIRCULATIONAHA.121.056135
11. Yonker LM, Swank Z, Bartsch YC, Burns MD, Kane A, Boribong BP, *et al.* Circulating spike protein detected in post-COVID-19 mRNA vaccine myocarditis. *Circulation* 2023;**147**:867–876. doi:10.1161/CIRCULATIONAHA.122.061025
12. Castruita JAS, Schneider UV, Møllerup S, Leineweber TD, Weis N, Bukh J, *et al.* SARS-CoV-2 spike mRNA vaccine sequences circulate in blood up to 28 days after COVID-19 vaccination. *APMIS* 2023;**131**:128–132. doi:10.1111/apm.13294
13. Avolio E, Carrabba M, Milligan R, Kavanagh Williamson M, Beltrami AP, Gupta K, *et al.* The SARS-CoV-2 Spike protein disrupts human cardiac pericytes function through CD147 receptor-mediated signalling: A potential non-infective mechanism of COVID-19

- microvascular disease. *Clin Sci (Lond)* 2021;**135**:2667-2689. doi:10.1042/CS20210735
14. Coronavirus (COVID-19) update: June 25, 2021 [Internet]. U.S. Food and Drug Administration. 2021. Available from: <https://www.fda.gov/news-events/press-announcements/coronavirus-covid-19-update-june-25-2021>. Accessed 23 May 2023
  15. Rose J, McCullough P. Determinants of COVID-19 vaccine-induced myocarditis requiring hospitalization. 2022. doi:10.5281/zenodo.6556390.
  16. Nonclinical evaluation of BNT162b2 [mRNA] COVID-19 vaccine (COMIRNATY) [Internet]. Australian Government Department of Health—Therapeutic Goods Administration; 2021 [cited 2023 May 23]. Available from: <https://www.tga.gov.au/sites/default/files/foi-2389-06.pdf>. Accessed 23 May 2023
  17. Baumeier C, Aleshcheva G, Harms D, Gross U, Hamm C, Assmus B, et al. Intramyocardial inflammation after COVID-19 vaccination: An endomyocardial biopsy-proven case series. *Int J Mol Sci* 2022;**23**:6940. doi:10.3390/ijms23136940
  18. Mansangan S, Charunwatthana P, Piyaphanee W, Dechkajorn W, Poolcharoen A, Mansangan C. Cardiovascular manifestation of the BNT162b2 mRNA COVID-19 vaccine in adolescents. *Trop Med Infect Dis* 2022; **7**:196. doi:10.3390/tropicalmed7080196
  19. Buerger N, Lopez-Ayala P, Hirsiger JR, Mueller P, Median D, Glarner N, et al. Sex-specific differences in myocardial injury incidence after COVID-19 mRNA-1273 booster vaccination. *Eur J Heart Fail* 2023;**25**:1871-1881. doi:10.1002/ejhf.2978
  20. Myocarditis and pericarditis after COVID-19 vaccination: Clinical management guidance for healthcare professionals. 2023. Available from: <https://www.gov.uk/government/publications/myocarditis-and-pericarditis-after-covid-19-vaccination/myocarditis-and-pericarditis-after-covid-19-vaccination-guidance-for-healthcare-professionals> Accessed 23 May 2023
  21. Guidance on myocarditis and pericarditis after COVID-19 vaccines. 2022. Available from: <https://www.health.gov.au/sites/default/files/documents/2022/11/covid-19-vaccination-guidance-on-myocarditis-and-pericarditis-after-covid-19-vaccines.pdf> Accessed 23 May 2023
  22. Vaccine Adverse Event Reporting System (VAERS) [online]. Available at: <https://vaers.hhs.gov> Accessed 23 May 2023
  23. Meissner CH. Vaccine Adverse Event Reporting System plays vital role in safety [Internet]. 2016 [cited 2023 Jul 6]. Available from: <https://publications.aap.org/aapnews/news/14631>
  24. Walach H, Klement RJ, Aukema W. The safety of COVID-19 vaccinations—Should we rethink the policy? *Sci, Publ Health Pol Law* 2021;**3**:87-99.
  25. Scarl R, Parkinson B, Arole V, Hardy T, Allenby P. The hospital autopsy: The importance in keeping autopsy an option. *Autops Case Rep* 2022;**17**:e2021333. doi:10.4322/acr.2021.333
  26. Nishida H, Ito A, Kurata H, Umemoto H, Tokunaga I, Iseki H, et al. A case of fatal multi-organ inflammation following COVID-19 vaccination. *Leg Med (Tokyo)* 2023;**63**:102244. doi:10.1016/j.legalmed.2023.102244
  27. Mörz M. A case report: Multifocal necrotizing encephalitis and myocarditis after BNT162b2 mRNA vaccination against COVID-19. *Vaccines (Basel)* 2022; **10**:1651. doi:10.3390/vaccines10101651
  28. Takahashi M, Kondo T, Yamasaki G, Sugimoto M, Asano M, Ueno Y, et al. An autopsy case report of aortic dissection complicated with histiolymphocytic pericarditis and aortic inflammation after mRNA COVID-19 vaccination. *Leg Med (Tokyo)* 2022;**59**:102154. doi:10.1016/j.legalmed.2022.102154
  29. Satomi H, Katano H, Kanno H, Kobayashi M, Ohkuma Y, Hashidume N, et al. An autopsy case of fulminant myocarditis after severe acute respiratory syndrome coronavirus 2 vaccine inoculation. *Pathol Int* 2022;**72**:519-524. doi:10.1111/pin.13267
  30. Suzuki H, Ro A, Takada A, Saito K, Hayashi K. Autopsy findings of post-COVID-19 vaccination deaths in Tokyo Metropolis, Japan, 2021. *Leg Med (Tokyo)* 2022;**59**:102134. doi:10.1016/j.legalmed.2022.102134
  31. Gill JR, Tashjian R, Duncanson E. Autopsy histopathologic cardiac findings in 2 adolescents following the second COVID-19 vaccine dose. *Arch Pathol Lab Med* 2022;**146**:925-929. doi:10.5858/arpa.2021-0435-SA
  32. Ameratunga R, Woon ST, Sheppard MN, Garland J, Ondruschka B, Wong CX, et al. First identified case of fatal fulminant necrotizing eosinophilic myocarditis following the initial dose of the Pfizer-BioNTech mRNA COVID-19 vaccine (BNT162b2, Comirnaty): An extremely rare idiosyncratic hypersensitivity reaction. *J Clin Immunol* 2022; **42**:441-447. doi:10.1007/s10875-021-01187-0
  33. Choi S, Lee S, Seo JW, Kim MJ, Jeon YH, Park JH, et al. Myocarditis-induced sudden death after BNT162b2 mRNA COVID-19 vaccination in Korea: Case report focusing on histopathological findings. *J Korean Med Sci* 2021;**36**:e286. doi:10.3346/jkms.2021.36.e286
  34. Schneider J, Sottmann L, Greinacher A, Hagen M, Kasper HU, Kuhn C, et al. Postmortem investigation of fatalities following vaccination with COVID-19 vaccines. *Int J Leg Med* 2021;**135**:2335-2345. doi:10.1007/s00414-021-02706-9
  35. Verma AK, Lavine KJ, Lin CY. Myocarditis after Covid-19 mRNA vaccination. *N Engl J Med* 2021;**385**:1332-1334. doi:10.1056/NEJMc2109975
  36. Schwab C, Domke LM, Hartmann L, Stenzinger A, Longerich T, Schirmacher P. Autopsy-based histopathological characterization of myocarditis after anti-SARS-CoV-2-vaccination. *Clin Res Cardiol* 2023;**112**:431-440. doi:10.1007/s00392-022-02129-5
  37. Hoshino N, Yanase M, Ichiyasu T, Kuwahara K, Kawai H, Muramatsu T, et al. An autopsy case report of fulminant myocarditis: Following mRNA COVID-19 vaccination. *J Cardiol Cases* 2022;**26**:391-394. doi:10.1016/j.jccase.2022.06.006
  38. Dong YM, Liu X, Yang CT, Qi Q, Shi WB, Li YM, et al. Case report: Myocarditis following COVID-19 protein subunit vaccination. *Front Cardiovasc Med* 2022; **9**:970045. doi:10.3389/fcvm.2022.970045
  39. Cho JY, Kim KH, Lee N, Cho SH, Kim SY, Kim EK, et al. COVID-19 vaccination-related myocarditis: A Korean nationwide study. *Eur Heart J* 2023;**44**:2234-2243. doi:10.1093/eurheartj/ehad339
  40. Fedak KM, Bernal A, Capshaw ZA, Gross S. Applying the Bradford Hill criteria in the 21st century: How data integration has changed causal inference in molecular epidemiology. *Emerg Themes Epidemiol* 2015;**30**:14. doi:10.1186/s12982-015-0037-4
  41. Polykretis P, McCullough PA. Rational harm-benefit assessments by age group are required for continued COVID-19 vaccination. *Scand J Immunol* 2022 Dec;**28**:e13242. doi:10.1111/sji.13242
  42. Cadegiani FA. Catecholamines are the key trigger of COVID-19 mRNA vaccine-induced myocarditis: A compelling hypothesis supported by epidemiological, anatomopathological, molecular, and physiological findings. *Cureus* 2022;**14**:e27883. doi:10.7759/cureus.27883
  43. Dodt C, Breckling U, Derad I, Fehm HL, Born J. Plasma epinephrine and norepinephrine concentrations of healthy humans associated with nighttime sleep and morning arousal. *Hypertension* 1997;**30**:71-76. doi:10.1161/01.hyp.30.1.71
  44. Wangu Z, Swartz H, Doherty M. Multisystem inflammatory syndrome in children (MIS-C) possibly secondary to COVID-19 mRNA vaccination. *BMJ Case Rep* 2022;**15**:e247176. doi:10.1136/bcr-2021-247176
  45. Ehihametalor K, Deans-Minott J, Duncan JP. Multisystem inflammatory syndrome in adults (MIS-A) after COVID-19 infection and recent vaccination with recombinant adenoviral vector encoding the spike protein antigen of SARS-CoV-2 (ChAdOx1 nCoV-19, Vaxzevria). *J Intensive Care Med* 2023; **38**:232-237. doi:10.1177/08850666221121589
  46. Ittiwut C, Mahasirimongkol S, Srisont S, Ittiwut R, Chockjamsai M, Durongkadech P, et al. Genetic basis of

- sudden death after COVID-19 vaccination in Thailand. *Heart Rhythm* 2022; **19**:1874-1879. doi:10.1016/j.hrthm.2022.07.019
47. Engler RJ, Nelson MR, Collins LC Jr, Spooner C, Hemann BA, Gibbs BT, *et al.* A prospective study of the incidence of myocarditis/pericarditis and new onset cardiac symptoms following smallpox and influenza vaccination. *PLoS ONE* 2015; **10**:e0118283. doi:10.1371/journal.pone.0118283
  48. Schmeling M, Manniche V, Hansen PR. Batch-dependent safety of the BNT162b2 mRNA COVID-19 vaccine. *Eur J Clin Invest* 2023; **53**:e13998. doi:10.1111/eci.13998
  49. Ogata AF, Cheng CA, Desjardins M, Senussi Y, Sherman AC, Powell M, *et al.* Circulating severe acute respiratory syndrome coronavirus 2 (SARS-CoV-2) vaccine antigen detected in the plasma of mRNA-1273 vaccine recipients. *Clin Infect Dis* 2022; **74**:715-718. doi:10.1093/cid/ciab465
  50. Keshavarz P, Yazdanpanah F, Emad M, Hajati A, Nejati SF, Ebrahimian Sadabad F, *et al.* Myocarditis following COVID-19 vaccination: Cardiac imaging findings in 118 studies. *Tomography* 2022; **8**:1959-1973. doi:10.3390/tomography8040164
  51. Giurgea LT, Morens DM. Great expectations of COVID-19 herd immunity. *MBio* 2022; **13**:e0349521. doi:10.1128/mbio.03495-21
  52. Pantazatos S, Seligmann H. COVID vaccination and age-stratified all-cause mortality risk. *Research Gate* 2021; doi:10.13140/RG.2.2.28257.43366
  53. Skidmore M. The role of social circle COVID-19 illness and vaccination experiences in COVID-19 vaccination decisions: An online survey of the United States population. *BMC Infect Dis* 2023; **23**:51. doi:10.1186/s12879-023-07998-3 Retraction in: *BMC Infect Dis* 2023 Apr 11; **23**(1):223. PMID: 36694131; PMCID: PMC9872073
  54. Aarstad J, Kvitastein OA. Is there a link between the 2021 COVID-19 vaccination uptake in Europe and 2022 excess all-cause mortality? 2023. 10.20944/preprints202302.0350.v1
  55. Beesoon S, Bakal JA, Youngson E, Williams KP, Berzins SA, Brindle ME, *et al.* Excess deaths during the COVID-19 pandemic in Alberta, Canada. *IJID Reg* 2022; **5**:62-67. doi:10.1016/j.ijregi.2022.08.011
  56. Todd M, Scheeres A. Excess mortality from non-COVID-19 causes during the COVID-19 pandemic in Philadelphia, Pennsylvania, 2020-2021. *Am J Public Health* 2022; **112**:1800-1803. doi:10.2105/AJPH.2022.3070962
  57. Karlinsky A, Kobak D. The World Mortality Dataset: Tracking excess mortality across countries during the COVID-19 pandemic. *medRxiv* 2021; 2021.01.27.21250604. doi:10.1101/2021.01.27.21250604
  58. COVID-19 Excess Mortality Collaborators. Estimating excess mortality due to the COVID-19 pandemic: A systematic analysis of COVID-19-related mortality, 2020-21. *Lancet* 2022; **399**:1513-1536. doi:10.1016/S0140-6736(21)02796-3
  59. Msemburi W, Karlinsky A, Knutson V, Aleshin-Guendel S, Chatterji S, Wakefield J. The WHO estimates of excess mortality associated with the COVID-19 pandemic. *Nature* 2023; **613**:130-137. doi:10.1038/s41586-022-05522-2
  60. Shang W, Wang Y, Yuan J, Guo Z, Liu J, Liu M. Global excess mortality during COVID-19 pandemic: A systematic review and meta-analysis. *Vaccines (Basel)* 2022; **10**:1702. doi:10.3390/vaccines10101702